



PATIENT

Lily Baum

SPECIES

Canine

BREED

Labrador Retriever

SEX

Female Spayed

AGE

10 years

WEIGHT

70lbs

INTERPRETED BY

Maggie Machen Lamy,
DVM, DACVIM
(Cardiology)

IMAGING PERFORMED BY

Striano-Kaplan, DVM

HOSPITAL NAME

Ramsey VH

REFERRING VET

Dr. Striano-Kaplan

INVOICE

46194

DATE

12/15/25

PRESENTING CLINICAL SIGNS

History: Recent CXR showed mild cardiomegaly. Diarrhea and vomiting. BP: 115mmHg. Labs: WNL. ECG showed axis deviation.

ECHOCARDIOGRAM FINDINGS

2D, m-mode, color flow and doppler imaging is available. Mild MV thickening with no prolapse into the left atrial lumen. Trivial mitral regurgitation with a normal left atrial dimension. Normal LV diameter with adequate myocardial function. The tricuspid valve appears normal with no tricuspid regurgitation. Normal right atrial and ventricular diameter and morphology indicating no overt evidence of pulmonary arterial hypertension. The pulmonic and aortic valves are normal in morphology and mobility. Normal pulmonic and aortic outflow velocities with laminar flow. No obvious aortic and trace pulmonic insufficiency. No pericardial or pleural effusion noted. No obvious cardiac masses.

CARDIAC CHART

CANINE CARDIAC PARAMETERS	MR VMAX (m/s)	TR VMAX (m/s)	LA/AO (Boon method)	LA/AO (Heart Base; Swe)	FS (%)	EF (%)	EPSS (cm)
NORMAL PARAMETER	4.5-5.5	<2.7	1.3	<1.6	28-40	40-100	<0.6
PATIENT	NA	NA	NM	1.3	35	65	0.2
CANINE CARDIAC PARAMETERS	HR (BPM)	AV VMAX (m/s)	PV MAX (m/s)	BODY WEIGHT (kg)	LA 2D short axis Base view (cm)	LVIDd Avg; 2D and m-mode short axis (cm)	LVIDs Avg; 2D and m-mode short axis (cm)
NORMAL PARAMETER	50-100	0.7-1.7	0.7-1.6	BELOW	BELOW	BELOW	BELOW
PATIENT	NM	0.8	0.8	31.8	2.3	3.7	2.4
*Normal chamber parameters expressed as a mean value (SD)				3	1.27 (5.3)	2.46 (2.46)	1.36 (5.5)
BODY WEIGHT DEPENDENT PARAMETERS				5	1.40 (4.5)	2.74 (5.2)	1.60 (4.7)
<i>*Note: All measurements based upon multi-modal images and methods. An average value is reported.</i>				10	1.50 (3.8)	3.27 (3.5)	2.06 (3.1)
				15	1.83 (2.0)	3.71 (2.4)	2.43 (2.1)
				20	2.02 (1.9)	4.14 (2.2)	2.80 (2.0)
Adapted from June Boon, Veterinary Echocardiography, 1998				25	2.18 (2.4)	4.48 (2.9)	3.10 (2.5)
Rishniw M and Hollis NE, J Vet Intern Med 2000; 14:429-435				30	2.33 (3.3)	4.83 (3.9)	3.39 (3.4)
Hansson et al, Vet Rad and Ultrasound 2002				35	2.48 (4.3)	5.17 (5.0)	3.69 (4.5)
Bonagura et al. Echocardiography: principles of interpretation, Vet Clin North Am 15:1177, 1995				40	2.62 (5.2)	5.48 (6.1)	3.96 (5.4)
				50	2.88 (7.1)	6.07 (8.3)	4.46 (7.4)

INTERPRETATION OF THE FINDINGS & FURTHER RECOMMENDATIONS

Overtly normal cardiac dimensions and function, with no obvious dysfunction or dilation of the left heart. No significant valvular leaks are visualized, and no evidence of pulmonary hypertension.

These findings would suggest the radiographic appearance is likely a normal variant. These films should be used as a baseline for future comparison. Additionally, no obvious intra or extra-cardiac masses are seen; however, it is important to note that they are easily missed in the absence of effusion. Consider a thoracic CT scan if suspicion is high.

No medications are indicated and the prognosis is open from a cardiac standpoint.



PATIENT

Lily Baum

Monitor for development of a heart murmur, cough, labored breathing, exercise intolerance or collapse episodes.

SPECIES

Canine

A recheck echocardiogram is recommended should a significant murmur develop or signs of cardiac compromise be noted in the future.

BREED

Labrador Retriever

SEX

Female Spayed

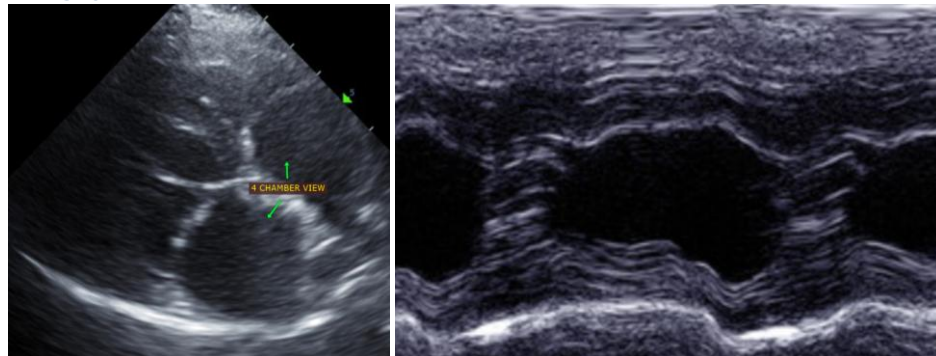
AGE

10 years

WEIGHT

70lbs

IMAGES



The information and recommendations provided are based on the images presented by the referring veterinarian. No evaluation can be communicated regarding pathology that was not visible in the image/video clips provided.

INTERPRETED BY

Maggie Machen Lamy,
DVM, DACVIM
(Cardiology)

Thank you for this referral. This report was generated using transcription software, and minor dictation errors may be present. If the clinical or image interpretation does not parallel your findings or if I can be of any further assistance, please contact me.

IMAGING PERFORMED BY

Striano-Kaplan, DVM

Maggie Machen Lamy, DVM
Diplomate of the American College of Veterinary Internal Medicine (Cardiology)
info@sonopath.com

HOSPITAL NAME

Ramsey VH

REFERRING VET

Dr. Striano-Kaplan

INVOICE

46194

DATE

12/15/25